

# UNDERSTANDING FRACTURE BLISTERS: Management and Implications

*Thomas F. Smith, DPM*

*Richard P. Bui, DPM*

*Cathy O. Coker, DPM*

## INTRODUCTION

The overlying premise to understanding the etiology, occurrence, and treatment of fracture blisters is that basically they are a clinical dilemma. Their true etiology is unknown. The occurrence and location of this troublesome condition relative to various injuries and injury patterns is unpredictable. A minor ankle sprain or minor blunt trauma may develop a fracture blister whereas a more major fracture or contusion may not. No universal consensus exists in terms of treatment of fracture blisters or their impact on subsequent surgery. Prognosis is poorly understood in terms of outcomes based on a range of treatment options in various possible patient populations. This uncertainty is primarily due to a relative scarcity of scientific attention or investigation. Their occurrence is more troublesome in terms of implications impacting management decisions for the underlying osseous or soft tissue injury not the blister itself. This paper is presented to discuss and review current knowledge about this relatively common condition that is unique to the distal extremities.

## INCIDENCE

Shelton, in 1986, defined fracture blisters as “skin bullae and blisters representing areas of epidermal necrosis with separation of the stratified squamous cell layer from the underlying vascular dermal layer by edema fluid.”<sup>1</sup> Their etiology has been hypothesized as both a mechanical shear of the skin relative to the mechanism of injury or a release mechanism of tissue pressure as a result of post-traumatic edema. Their size, shape, location, pattern, and position are variable and unpredictable. Fracture blisters are in and of themselves painless much like a friction blister or blister of a second degree burn. The primary injury itself may be painful. There is no correlation with age, sex, or race. No correlation has been noted with initial fracture care or concomitant injury as well as the general health status of the patient.

Fracture blisters are more commonly associated with high-energy trauma (Figure 1). In a study by Varela et al, 25% were classified as low-energy trauma such as slips or twisting injuries.<sup>2</sup> This finding is likewise noted in acute compartment syndrome where milder injury can result in high compartment pressures whereas more severe injuries do not. Fracture blisters can be seen in open fractures, but are rare. Fracture blisters can occasionally be seen to form even after uneventful elective foot and ankle surgery (Figure 2). Fracture blisters may appear as early as 6 hours following an injury or surgery or could appear as late as three weeks. They typically occur within 24-48 hours following injury. Their exact onset can be difficult to determine if overlying dressings were covering and hiding the extremity injury site (Figure 3).

If all fractures are considered, there is a 2.9% incidence of fracture blister formation. When comparing only those injuries prone to form fracture blisters, the incidence rises to 5.2%. They can rarely but occasionally be noted after non-traumatic elective reconstructive foot and ankle surgery. Fracture blisters are typically located distal to the mid-shaft of the humerus in the upper extremity and distal to the knee in the lower extremity. Conclusions based on the presence of

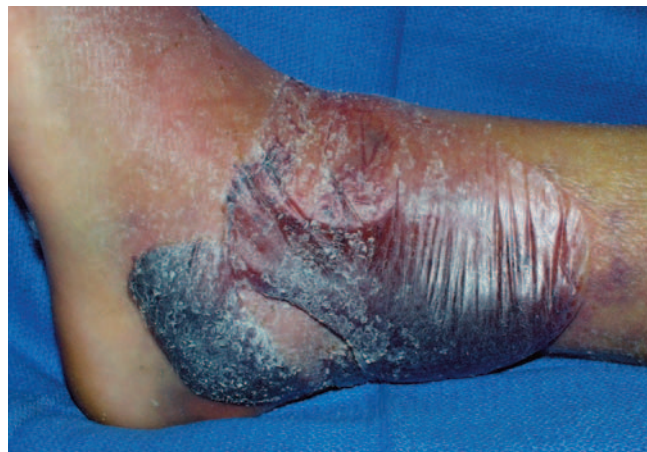

Figure 1. Blood-filled fracture blister associated with a closed bimalleolar ankle fracture.

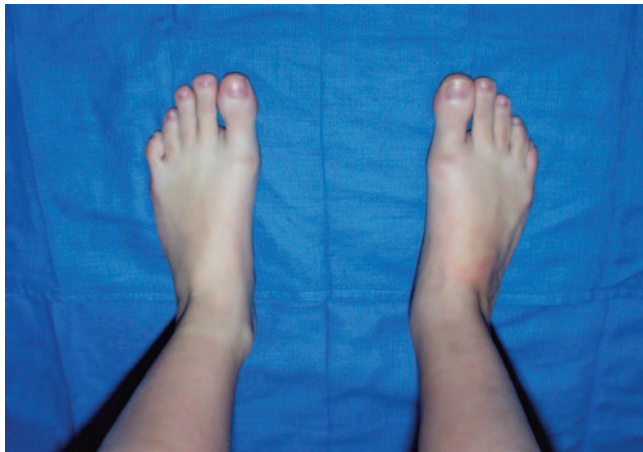

Figure 2A. Preoperative view.

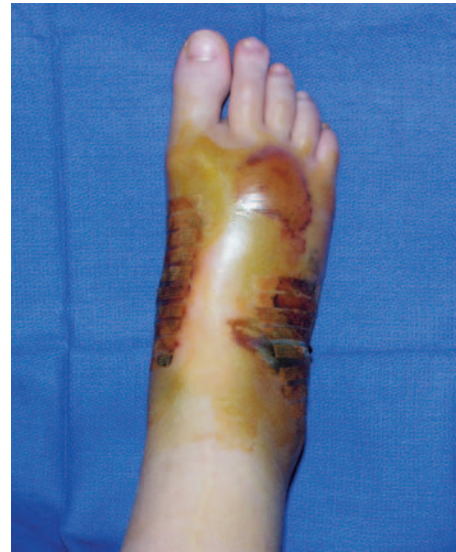

Figure 2B. Two-week postoperative view.

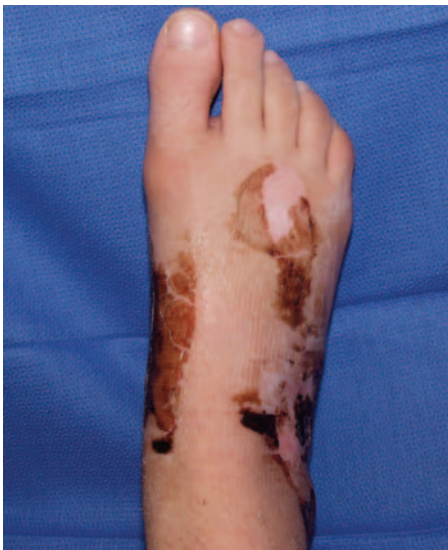

Figure 2C. Six-week postoperative fluid-filled fracture blister following elective reconstructive rearfoot surgery.

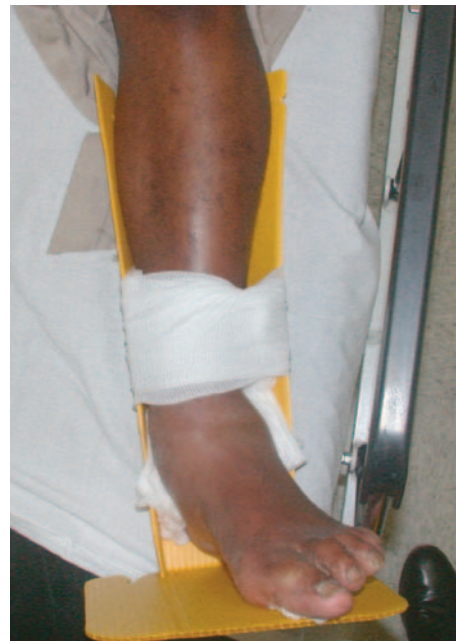

Figure 3A. Emergency room presentation without fracture blisters.

fracture blisters are inconclusive in terms of the severity of the injury, timing of the injury, or the appropriateness of treatment or patient compliance as well as the health history of the patient.

## MORPHOLOGY

Two types of fracture blisters are possible, namely clear fluid-filled and blood-filled fracture blisters. Both types may occur on the same patient over the same fracture (Figure 4). Neither fluid- nor blood-filled fracture blisters are a

predictor of the severity of the injury or the general health status of the patient. Clear fluid-filled fracture blisters demonstrate a cleavage within the epidermis itself with a partial epidermal and dermal base. Clear fluid-filled fracture blisters are termed subcorneal in terms of histological location within the epidermis of the skin. The cleavage to form the clear fluid-filled fracture blister occurs above the granular layer of the epidermis. These fracture blisters heal without scar or pigmentation changes to the skin.

The blood-filled fracture blisters demonstrate separation or cleavage of the epidermis from the dermis. The roof of the

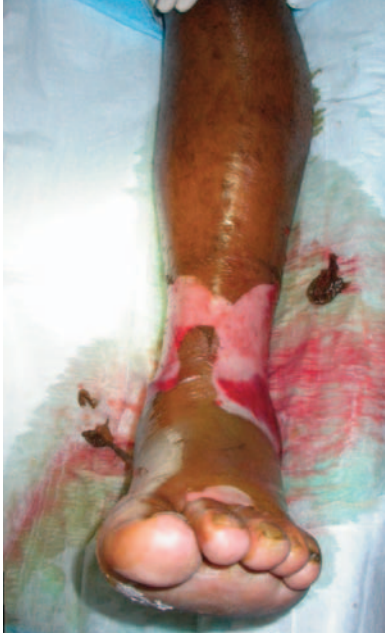

Figure 3B. Operating room presentation with fluid-filled fracture blisters associated with an ankle pilon fracture.

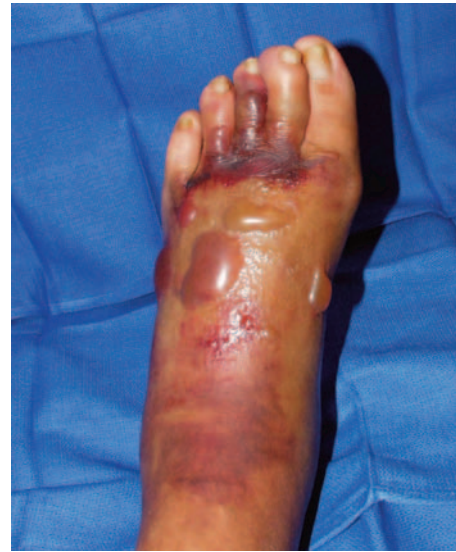

Figure 4A. Fluid-filled fracture blister.

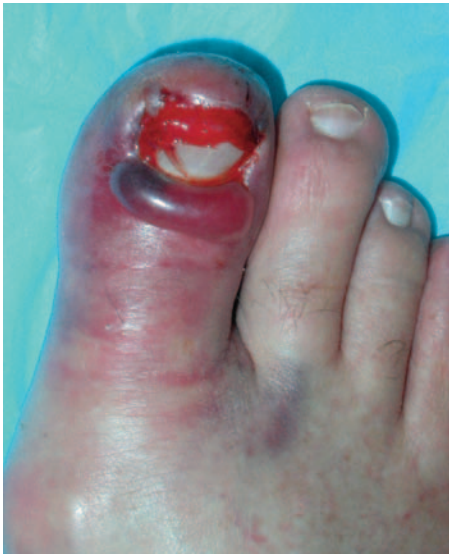

Figure 4B. Blood-filled fracture blister.

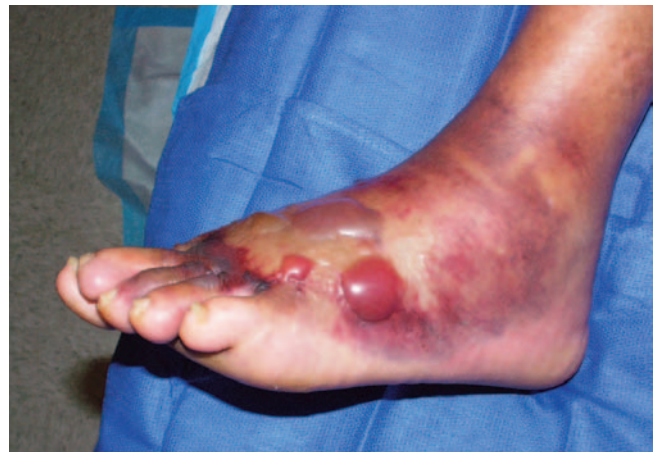

Figure 4C. Combination fluid and blood-filled fracture blisters on the same patient with a wide distribution of fracture blisters even to the digits with trauma to the midfoot.

blister comprises the entire epidermis and the base is the dermis. In blood-filled fracture blisters, the vasculature of the papillary dermis is damaged allowing bleeding into the blister cavity. These blisters represent a more significant injury to the skin both histologically and clinically. The entire epidermis over the blister site becomes necrotic. Blood-filled fracture blisters can heal with dermal scarring and pigmentation changes to the skin. Later evidence of scarring or pigmentation changes to the skin may be used to clinically determine the former presence of a blood-filled

fracture blister over a fluid-filled fracture blister. No assumptions can be made, however, if such scarring is present of the former severity of the injury or its management at the time. Re-epithelialization is expected by 13 days in clear fluid-filled fracture blisters and by 16 days in blood-filled fracture blisters. The faster healing time of clear fluid-filled fracture blisters may be related to retention of a degree of epidermis to the fracture blister bed not present in the blood-fluid filled blisters.

The fluid within a fracture blister is sterile, but



demonstrates significant colonization with multiple organisms upon rupture. The fluid is an ideal culture medium with no competing organisms and the absence of phagocytes. Most organisms noted are opportunistic resident skin flora, primarily *S. aureus* and *S. epidermidis*. Infection can easily occur in this area of skin compromise. The fracture blister fluid medium and the compromised microcirculation of the dermis, especially in blood-filled blisters, invite colonization and the potential for infection. Bacterial colonization will persist until re-epithelialization occurs to protect the skin. Negative cultures do not typically present until an average of 12 days after blister rupture, which is an average of 18 days following the injury. The fracture fluid itself in terms of histology and chemical analysis is similar to that seen in friction blisters. Compartment pressure measurements have been noted to be markedly elevated before fracture blister formation and reduced after fracture blister formation. Few patients have symptoms or signs of compartment syndrome associated with fracture blisters due to the relative lack of underlying muscle in those anatomic areas prone to fracture blister formation. Their location and occurrence is primarily over areas of little muscle mass and bone prominence with little soft tissue between bone and skin such as the distal extremities including the ankle, leg, foot, and elbow.

## PATHOGENESIS

The most serious concerns with fracture blisters are skin compromise with surgical incisions and infection. Post-operative infections in incisions near or within the fracture blister itself represent the greatest long term risk in terms of morbidity with fracture blisters. This risk does not preclude the possibility of placing incisions within fracture blisters if clinically necessary (Figure 5). Fracture blisters and the associated swelling impacts both the circulation to the skin

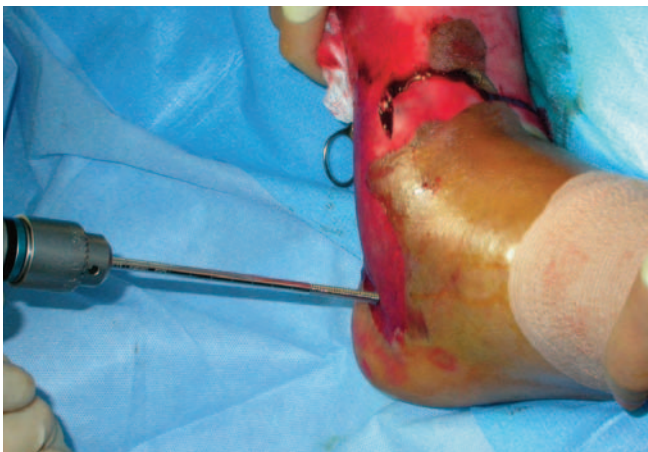


Figure 5. Placing a percutaneous pin for an external fixator through a de-roofed fluid-filled fracture blister bed.

and can play a prominent role in producing the blister cavity itself within the skin. The resultant skin compromise from a structural and circulatory standpoint can result in an increased susceptibility to wound infection and dehiscence even before a surgical incision is made. The clinical picture of marked swelling, edema, and elevated interstitial pressures of fracture blisters is not unlike acute compartment syndrome.

Elevated interstitial pressures following trauma can dissipate in three basic ways. First, if the intracompartmental pressure is only mildly elevated then interstitial fluid can be reabsorbed through the normal venous and lymph systems maintaining interstitial pressure equilibrium. Second, the intercompartmental pressure may be too high to be handled by the body physiologically, but not so high as to cause compartment syndrome. Interstitial pressure may be relieved in this instance by the formation of fracture blisters. Third, if the interstitial fluid overwhelms the system increasing intracompartmental pressure resulting in symptoms of compartment syndrome then a surgical fasciotomy to relieve pressure may be needed.

In a study by Varela et al, few patients with fracture blisters demonstrated sufficient signs and symptoms of compartment syndrome to warrant suspicion of undue elevation of the interstitial pressure in the soft tissues overlying the fractures, even with a high index of suspicion.<sup>2</sup> This is thought to be due not only to the relative absence of pressure-sensitive muscle in fracture blister prone sites reducing the incidence of symptoms, but the ability of pressure in these areas to dissipate along skin-fascial planes by the formation of fracture blisters. This is demonstrated clinically by calcaneal fractures where fracture blisters may form not just in the foot, but more proximally over the lower leg as well (Figure 4C). Areas of bony prominence with little natural soft tissue between the skin and bone are the most prone to fracture blister formation such as the ankle, elbow, and knee.

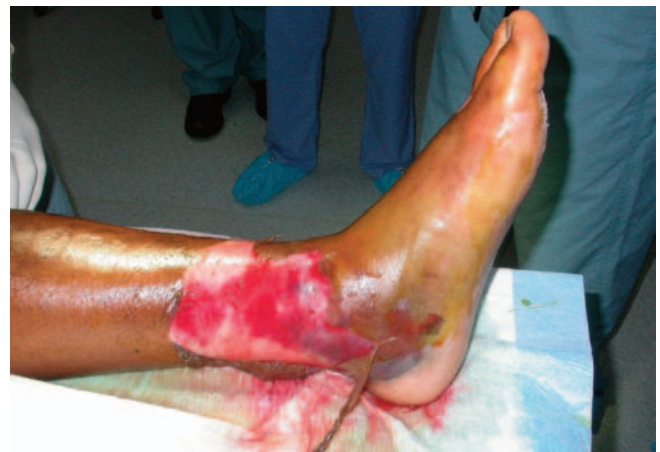

Figure 6. Ruptured fluid-filled fracture blister.

## TREATMENT

Healing of the fracture blisters themselves is generally uneventful and uncomplicated regardless of treatment.<sup>3</sup> Advocates can be found for rupturing or leaving them intact; de-roofing or not debriding; and wet or dry dressings with or without various topical medications (Figure 6). If no surgery is planned involving the blister or blister site, typically the blister is left intact. The roof of the blister provides an effective mechanical barrier to infection acting as a sterile biological dressing. Removal of the roof through debridement results in rapid colonization of the blister bed. Healing has been observed to be quicker under moist dressings as utilized for the blisters of second degree burns rather than occlusive dressings. Topical silver sulfadiazine has been shown to help in minimizing soft tissue complications and promote re-epithelialization in non-diabetic patients.<sup>4</sup> Soft dressings can be applied to maintain the blister until re-epithelialization can occur. There is no precise understanding when the re-epithelialization process is completed and it is described variably from 4-21 days. Typically, there is little difficulty in healing the fracture blister itself (Figure 2C). The main concern is how fracture blisters may impact the management of an underlying fracture.

In those high-energy injuries where a high index of suspicion exists for the possibility of fracture blister formation, surgery should be considered early within a day or so before the possibility of fracture blisters to form. Early surgical intervention helps avoid incisions through potential fracture blister sites. Surgery reduces the incidence of fracture blisters through relief of tissue pressures by the act of the surgery itself, evacuation of any hematoma, and stabilization of any fractures present. Surgery in fracture blister prone sites within 24 hours has been shown to have little potential for fracture blister formation. Even when fracture blisters formed after a surgical intervention, little impact on the outcome was noted.

Once the fracture blisters have formed, three options are available. First, incisions can be placed in the bed of the

fracture blister if deemed clinically necessary. Second, surgical incisions can be placed to avoid the fracture blister sites. Third, surgery can be delayed until a degree of fracture blister healing has occurred. Incisions in the vicinity of fracture blisters can become compromised as the skin damage can extend beyond the fracture blister margin. Complications involving wound healing issues have been shown to be more likely with incisions through blood-filled fracture blisters rather than fluid-filled fracture blisters in a limited number of case reviews. Generally surgical interventions are delayed rather than making incisions through fresh fracture blister sites unless specifically necessary.

## CONCLUSION

Understanding both the implications of fracture blisters as well as their management is an important part of clinical practice for the podiatric surgeon. Fracture blisters do not necessarily imply the severity of injury to tissues whether acute, traumatic, or elective surgical. As opposed to representing the presence of increased interstitial pressures, they tend to represent more interstitial pressure release. Fracture blisters are more formidable in their impact on subsequent treatment options such as surgical incisions or percutaneous fixation once formed than their prognosis in terms of eventual uncomplicated healing. Fracture blisters can appear daunting to patients and the inexperienced clinician. Understanding more fully their pathogenesis and implications helps dissuade these fears.

## REFERENCES

1. Shelton ML, Anderson RL: Complications of Fractures and Dislocations of the Ankle. In: *Complications of Orthopaedic Surgery*, ed CH Epps Jr, editor. Philadelphia: JB Lippincott; 1988. p. 599-648.
2. Varela CD, et al. Fracture Blisters: Clinical and Pathological Aspects. *J Orthop Trauma* 1993;7:417-27.
3. Giordano CP, Koval KJ. Treatment of Fracture Blisters: A Prospective Study of 53 Cases. *J Orthop Trauma* 1995;9:171-6.
4. Strauss EJ, Petrucelli G, Bong M, Koval KJ, Egol KA: Blisters Associated with Lower-Extremity Fracture: Results of a Prospective Treatment Protocol. *J Orthop Trauma* 2006;20:618-22.