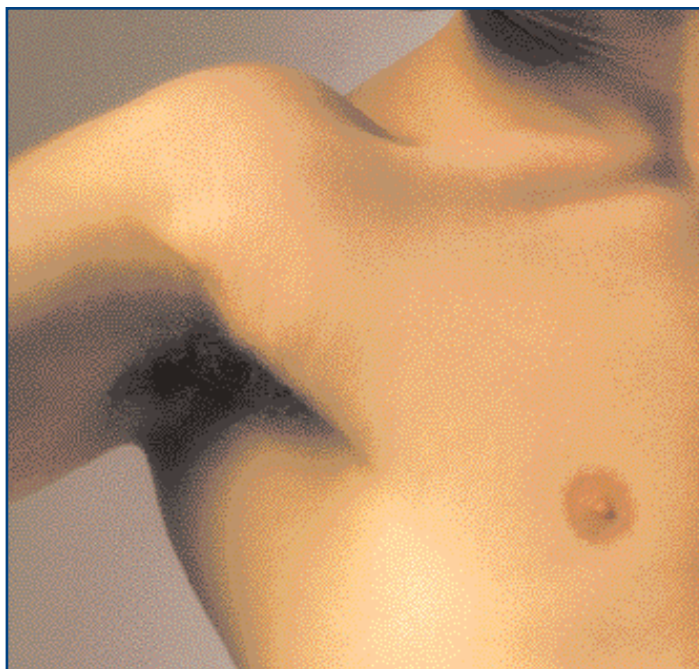


Recognition and Management of Common Forms of Tendinitis and Bursitis

Tendinitis and bursitis are common complaints, and are primarily due to overuse or repetitive microtrauma. This article focuses on supraspinatus tendinitis and subacromial bursitis, *pes anserine*, iliopsoas and trochanteric bursitis and lateral epicondylitis.

By Michael Starr, MD, FRCP(C), and Harbhajan Kang, MD



Dr. Starr is assistant professor of medicine, division of rheumatology, McGill University Health Centre, Montreal, Quebec.



Dr. Kang is fellow in rheumatology, McGill University Health Centre, Montreal, Quebec.

Tendinitis & Bursitis

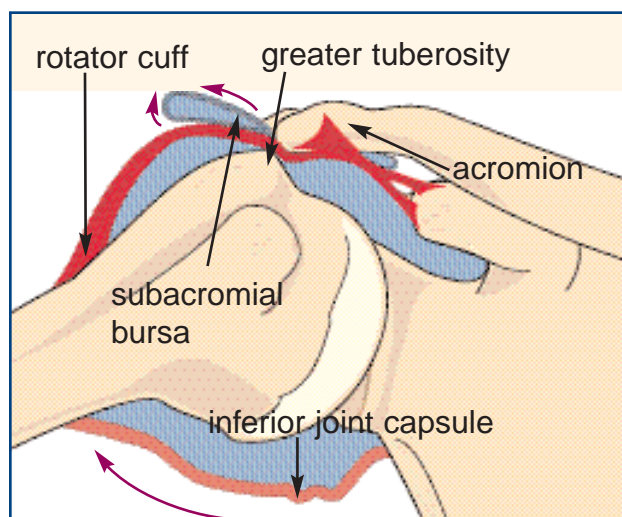


Figure 1. Impingement of the rotator cuff and subacromial bursa between the humeral head and overlying coracromial arch.

Adapted from Klippel JH: *Rheumatology*, Second Edition, 1998, Mosby, St. Louis, p. 4.7.2.

Tendinitis and bursitis are among the most frequent complaints of patients visiting primary-care physicians. These injuries commonly occur with overuse or repetitive microtrauma. Less common etiologies include crystal deposition, infection, inflammatory disease and hemorrhage. In this article, the authors will discuss the clinical manifestations, investigations and management of supraspinatus tendinitis and subacromial bursitis, *pes anserine* bursitis, iliopsoas bursitis, trochanteric bursitis and lateral epicondylitis.

Supraspinatus Tendinitis and Subacromial Bursitis

Supraspinatus tendinitis and subacromial bursitis are the most common causes of shoulder pain. They are grouped together, since their clinical findings are often indistinguishable and their man-

agement is similar.

The shoulder is composed of the scapulothoracic articulation, and the sternoclavicular, acromioclavicular and glenohumeral joints. The rotator cuff consists of the supraspinatus, infraspinatus, teres minor and subscapularis muscles. These muscles stabilize the humeral head in the glenoid fossa during shoulder movement. Their tendons insert on the greater (*i.e.*, supraspinatus, infraspinatus and teres minor) and lesser (*i.e.*, subscapularis) humeral tuberosity. They also provide internal rotation (subscapularis), external rotation (teres minor and infraspinatus) and early abduction from 0° to 30° (supraspinatus). The subacromial bursa lies between the rotator cuff (mainly supraspinatus tendon) and the overlying acromion.

The most common cause of supraspinatus tendinitis and subacromial bursitis is the impingement syndrome.¹ Dysfunction of the rotator cuff muscles leads to superior migration of the humeral head during arm elevation, resulting in impingement of subacromial tissues (Figure 1). The impingement syndrome progresses over several stages. Initially, there is edema and hemorrhage of the tendon, followed by fibrosis of the subacromial bursa and eventual tendon degeneration and rupture.²

Other causes of shoulder tendinitis/bursitis include calcific tendinitis, trauma and primary inflammation (crystal deposition, infection or autoimmune conditions). Severe longstanding cases may progress to a secondary adhesive capsulitis/frozen shoulder. The mean age of onset of this complication is in the sixth decade, and it is more common in diabetic patients.²

Clinical manifestations. Patients present with progressive subdeltoid aching that is aggravated by abduction, elevation, or sustained overhead activity. The pain may radiate to the lateral upper arm. Note that pain in the posterior shoulder or trapezius region can derive from the cervical

spine. Other complaints include nocturnal pain and difficulty with dressing. The patient may have a history of sports or occupational repetitive trauma, however, this is not universal.

Clinical examination. The shoulders are inspected for symmetry, localized swelling and muscle atrophy. There may be tenderness below the acromion and over the greater tuberosity. Internal rotation of the shoulder can facilitate palpation of the supraspinatus insertion on the greater tuberosity. The most important clinical maneuvers are as follows:

Painful arc: The patient actively abducts the arm and a painful arc occurs between 70° and 120°. This is due to the compression of the supraspinatus tendon or subacromial bursa between the anterior acromial arch and humeral head (Figure 1). When lowering from full abduction there is often a painful “catch” at midrange. If the patient can achieve adequate muscle relaxation, passive motion tends to be less painful.

Neer’s sign: Pain occurs during forward elevation of the internally rotated arm above 90° (Figure 2a).³

Hawkin’s Sign: Impingement is demonstrated by forcibly internally rotating the proximal humerus when the arm is forward flexed to 90° (Figure 2b).

Supraspinatus challenge test (“The Empty Beer Can” sign): The arm is abducted to 90° and internally rotated. The arm is placed 30° anterior to the coronal plane, and the patient is asked to resist a downward force. This maneuver isolates the supraspinatus tendon. Pain indicates a positive test, and weakness may indicate a tear. (Figure 2c).³

Imaging. Diagnosis is usually clinical, but imaging can be useful. Shoulder x-rays can reveal calcifications in rotator cuff tendons and in the bursa. In longstanding cases, there may be degenerative changes, such as cystic/sclerotic changes at

the greater tuberosity and decreased humeral head-acromion distance, secondary to upward migration of the humeral head. In acute calcific tendinitis, calcifications may be irregular, fluffy and ill-defined.

Dynamic ultrasound can demonstrate thickening of the subacromial bursa and impingement during abduction. Magnetic resonance imaging (MRI), rather than computed tomography (CT), is the preferred modality, since it produces more detailed soft-tissue images.

Management. Early management includes

Dynamic ultrasound can demonstrate thickening of the subacromial bursa and impingement during abduction.

avoidance of repetitive movements that aggravate the pain. Gentle range-of-motion exercises, such as Codman’s classic pendulum exercises, maintain range of motion and prevent development of adhesive capsulitis.¹ Nonsteroidal anti-inflammatory drugs (NSAIDs) may be the first choice for mild to moderate symptoms, if there are no contraindications to these agents. Physiotherapy modalities, such as local ultrasound also may be

**Counseling the
HSV Patients**

- see page 125

Tendinitis & Bursitis

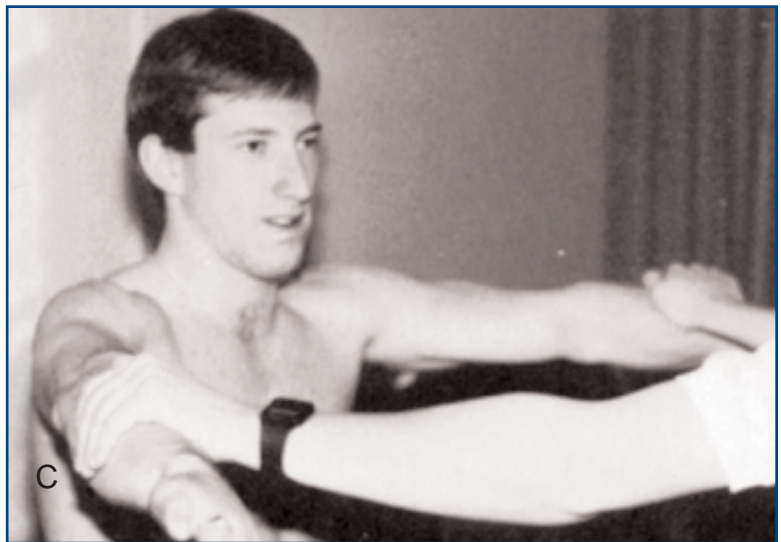

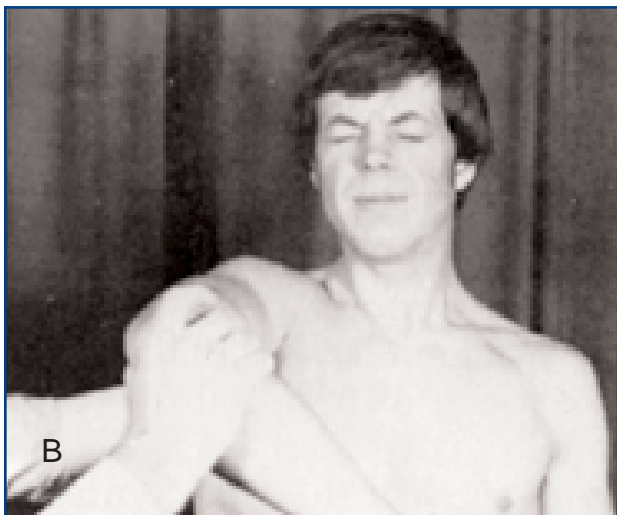Figure 2. Impingement signs.

A. Neer's sign

B. Hawkins sign

C. Empty beer can test

Photos from Magee DJ: *Orthopedic Physical Assessment*, 1987, WB Saunders, Philadelphia, PA. p. 78.



helpful. Moderate to severe symptoms may require a local subacromial corticosteroid injection. There is evidence that steroid injection is better than placebo in improving shoulder abduction.⁴ There are several techniques for intra-bursal injection, however, they are not always accurate, even when performed by physicians specialized in treating musculoskeletal disorders.⁵ Nevertheless, both intra- and peri-bursal injections may provide clinical benefit. Injections are best performed under ultrasound or fluoroscopic guidance, however, this is not always practical. A solution of 40 mg of methylprednisolone or triamcinolone with 1 to 3 ccs of 1% lidocaine without epinephrine can be used for injection (Figure 3). Never inject against resistance since this indicates that the needle may be within the tendon itself, thereby, increasing the risk of tendon

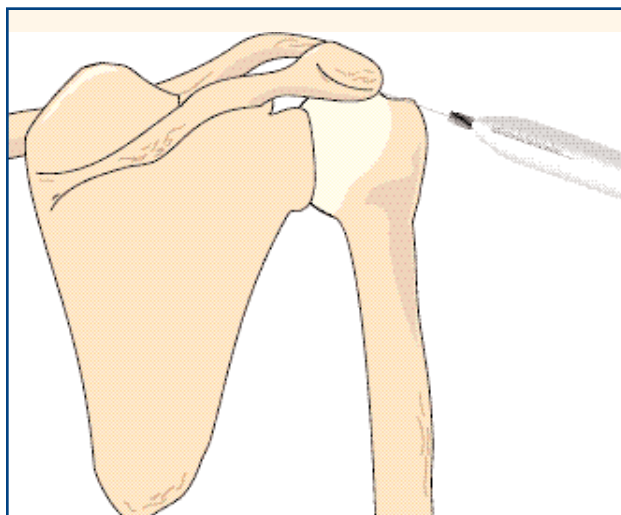


Figure 3. Posterolateral approach to the subacromial bursa.

Adapted from Klippel JH: *Rheumatology*, Second Edition, 1998, Mosby, St. Louis, p. 2.12.7.

degeneration and rupture. Immediate relief of symptoms, due to the effect of the local anaesthetic, helps confirm proper placement of the medication. Once pain has been reduced, a strengthening program focusing on the rotator cuff should be instituted.

Recently, a modified technique for suprascapular nerve block has been developed. This simple technique has the potential to be an additional treatment for rotator cuff tendinitis and adhesive capsulitis. The exact method is described by Dahan *et al* in the *Journal of Rheumatology*.⁶

Regarding specific treatment of calcific tendinitis, aggressive management is reserved for chronic treatment resistant cases, or shoulders with large calcium deposits. Invasive interventions include barbotage (multiple needle punctures) and aspiration/irrigation under radiographic guidance. Corticosteroid injection can be used if there is impingement and subacromial inflammation. Intensive ultrasound therapy has been shown

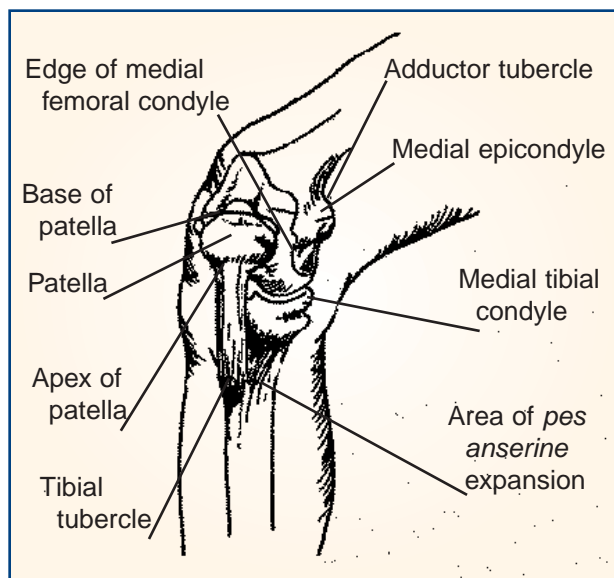


Figure 4. Landmarks of the knee. Location of pes anserine bursa.

Adapted from Magee DJ: *Orthopedic Physical Assessment*, 1987, WB Saunders, Philadelphia, PA, p. 303.

to increase calcium resorption, but this requires frequent treatment that may not always be practical.⁷ Surgical approaches include calcium deposit resection, with or without subacromial decompression, splitting of the coraco-acromial ligament, bursal resection and acromioplasty, using either arthroscopic or open methods. The major indication for surgery is ongoing pain, loss of function and failure to respond to one year of conservative therapy.

Pes Anserine Bursitis

The term *pes anserinus* (“goose’s foot”) refers to the conjoined tendons of the sartorius, semitendinosus and gracilis muscles, which attach to the medial surface of the upper tibia. This insertion is located two inches below the medial joint margin. The *pes anserinus* helps control medial rotation of

Tendinitis & Bursitis

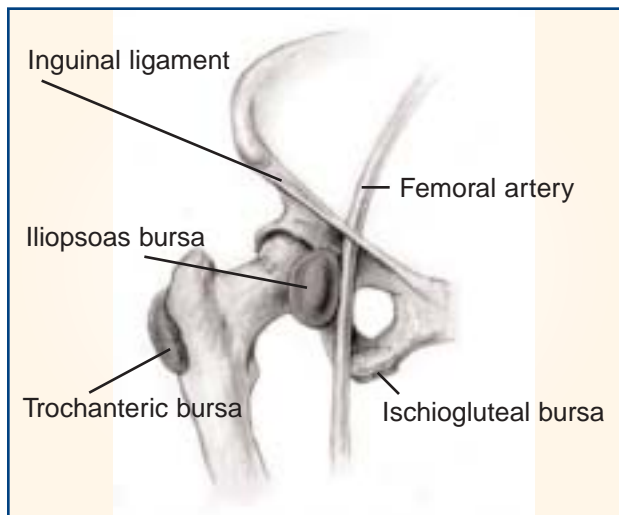


Figure 5. Bursae of the hip.

Adapted from Polley HF, Hunder GG: *Rheumatologic Interviewing and Physical Examination of the Joints*, 1978, WB Saunders, Philadelphia, PA, p. 183.

the flexed knee. The anserine bursa separates the medial collateral ligament from the tendons of the *pes anserinus* (Figure 4).

Clinical manifestations. Repetitive trauma can cause inflammation of this bursa, particularly in overweight females who have underlying knee osteoarthritis. Lying on one's side when the knees are opposed exacerbates pain. Consequently, patients prefer to sleep with a pillow between their knees. Pain is aggravated while walking up and down stairs and is less prominent while walking on level ground. Often, there is vague medial knee pain, which may mimic a meniscal or medial collateral ligament injury.

Examination, diagnosis and management. Tenderness and occasional swelling occurs along the proximal medial tibia. The diagnosis is usually clinical, however, ultrasound or MRI can detect fluid collections in the bursa.⁸ Management involves rest, local measures, such as ice or heat, and anti-inflammatories. If conservative measures

fail, corticosteroid injections to the bursa can be very helpful.

Iliopsoas bursitis

Iliopsoas bursitis is often difficult to recognize. The three main causes are rheumatoid arthritis, hip osteoarthritis and overuse injuries.

The iliopsoas tendon inserts on the lesser trochanter of the femur, and is involved in hip flexion and external rotation of the femur. The iliopsoas bursa is located between the iliopsoas muscle and the anterior capsule of the hip. Because of its proximity to the femoral nerves and vessels, enlargement of this bursa can result in compression of these structures (Figure 5).

Inflammation of this bursa occurs frequently in patients with gait abnormalities, and is common in overweight women with pre-existing hip arthritis.

In underlying hip disease, such as rheumatoid arthritis (RA) or osteoarthritis (OA), there is often a connection between the bursa and joint space. Due to its large size and potential for communication with the hip joint, the iliopsoas bursa is capable of accumulating large amounts of fluid.

Clinical Manifestations. Iliopsoas bursitis presents as pain, as a mass, or as a compressive syndrome in the inguinal and pelvic areas.^{9,10} Pain may occur with simple activities involving hip movement, such as putting on socks. It may radiate down the anterior thigh to the knee (likely from femoral nerve compression). A shortened stride may be an early sign, since hip hyperexten-

sion aggravates the pain.

An enlarged bursa can present as a palpable inguinal mass, which can be mistaken for entities, such as lymphadenopathy, hernia, tumor, or femoral artery aneurysm. Compressive symptoms include:

- 1) Venous obstruction leading to lower extremity edema or deep venous thrombosis (DVT);
- 2) Femoral neuropathy; and
- 3) Displacement of pelvic organs (*e.g.*, bladder compression).⁹

Bursitis resulting from overuse injury can present as a variant of the “Snapping hip syndrome,” which is characterized by an audible snapping sensation and pain during certain hip movements.¹¹ Sudden movement of the iliopsoas tendon over bony prominences produces the snap. Sports or occupation-related trauma to the bursa during vigorous hip flexion and extension is the usual mechanism of injury.

Imaging. Conventional x-rays are useful for showing underlying hip joint disorders (*e.g.*, rheumatoid or osteoarthritis). Ultrasound or arthrography/bursography can confirm the presence of fluid in the bursa and the extent of bursal enlargement. In unclear cases, CT/MRI can help confirm the diagnosis.

Diagnosis. Melamed *et al* have proposed a diagnostic triad consisting of (1) a palpable mass, (2) signs of compression of adjacent structures, and (3) radiographic evidence of advanced hip arthritis.⁹ This triad is appropriate for advanced iliopsoas bursitis secondary to RA or OA, however, it is insensitive for mild cases and those related to overuse. Relief of symptoms with ultrasound-guided injection of local anesthetic into the iliobursal region is a useful diagnostic maneuver.

Management. Limitation of hip motion, heat, and NSAIDs are indicated for mild cases. Aspiration of the bursa and injection with corticosteroids may be required for severe cases. Both

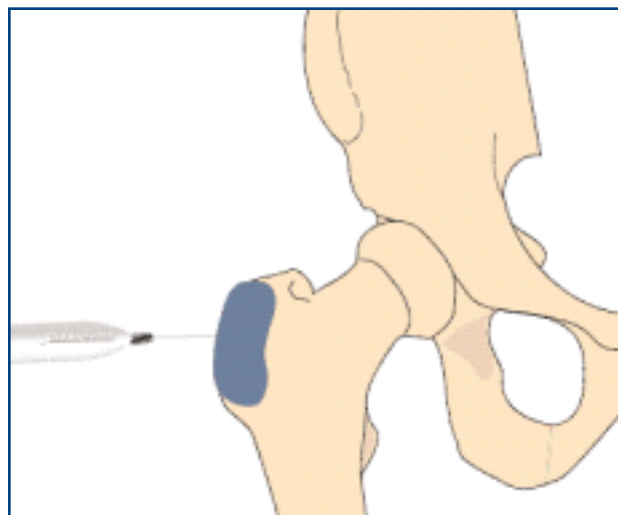


Figure 6. Injection of the trochanteric bursa. Adapted from Klippel JH: *Rheumatology*, Second Edition, 1998, Mosby, St. Louis, p. 2.12.9.

CT and ultrasound can be used as guides for needle aspiration and steroid injection. In cases where effusions recur, resection of the bursa may be required.

Physiotherapy may be particularly useful for overuse injuries.¹¹

Trochanteric Bursitis

The trochanteric bursa protects the soft tissues that cross the greater trochanter of the femur. Inflammation of this bursa occurs frequently in patients with gait abnormalities, and is common in overweight women with pre-existing hip arthritis. Trochanteric bursitis also may occur as an isolated condition.

Clinical manifestations. Patients complain of lateral thigh pain, which they may incorrectly refer to as “hip” pain. Pain is aggravated by walking, squatting and climbing stairs, and may radiate to the knee. Patients frequently report night pain,

Tendinitis & Bursitis

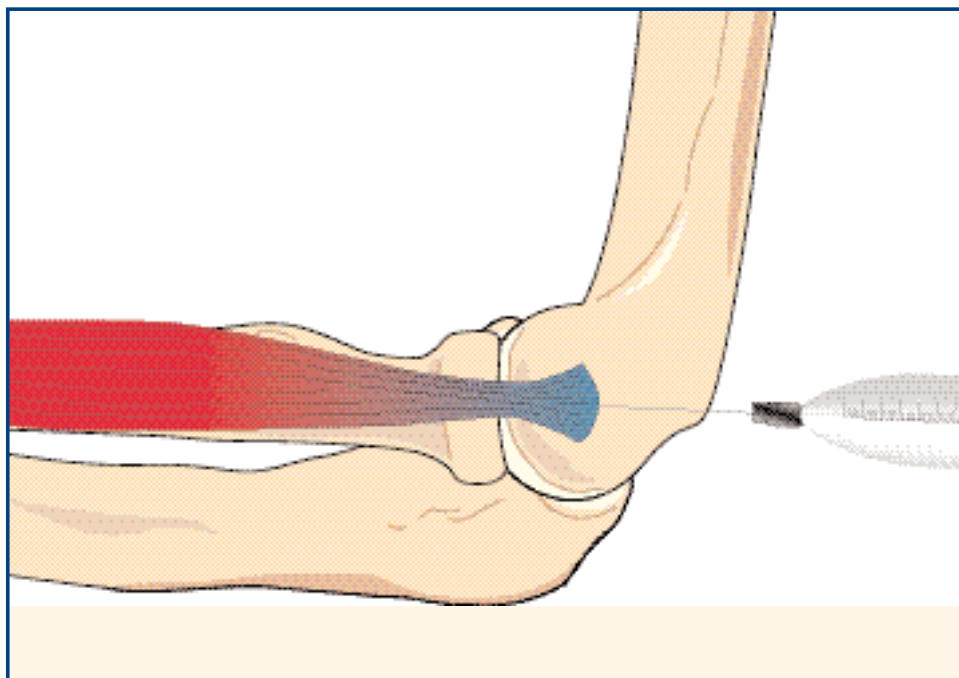


Figure 7. Injection in lateral epicondylitis.

Adapted from Klippel JH: *Rheumatology*, Second Edition, 1998, Mosby, St. Louis, p. 2.12.6.

which is exacerbated by lying on the affected side. Up to 15% of patients have a limp.

Examination. The hallmark is point tenderness over the greater trochanter. The bursa may feel boggy, particularly in thin patients. Hip range-of-motion is usually not affected, but discomfort can limit hip motion in severe cases. Groin pain is indicative of intrinsic hip disease. Resisted abduction of the hip may reproduce the lateral thigh pain.

Diagnosis is clinical. Radiography can show irregularities of the greater trochanter or calcifications of the bursa. Bone scintigraphy may show increased uptake, for which the differential diagnosis is stress fracture, infection, or bone/soft tissue tumor.²

Management.

Conservative therapy consists of rest, eliminating aggravating activities and physiotherapy. NSAIDs have a minimal role. A corticosteroid injection may be extremely helpful.¹² A mixture of 40 mg of methylprednisilone and 1 to 3 cc 1% lidocaine is injected at 90° into the point of maximal tenderness (Figure 6).

Occasionally, symptoms may persist, due to tightness of the iliotibial band. In such cases, physiotherapy may be helpful. A heel lift also can help if the cause is leg-length discrepancy.

Lateral Epicondylitis ("Tennis Elbow")

The forearm extensor tendons insert on the lateral epicondyle of the humerus. Lateral epicondylitis is caused by inflammation of these tendons and is a frequent cause of non-articular elbow pain. The majority of cases are due to chronic and repetitive injuries. Despite the term "tennis elbow," this condition is not isolated to athletes. Pain occurs over the lateral epicondyle and is aggravated by motions that stress the wrist extensor muscles, such as shaking hands, lifting a pot, etc.

Examination. There is tenderness to direct pal-

pation of the lateral epicondyle and its nearby sites. There may also be swelling, redness, and warmth over the point of maximal tenderness. Range-of-motion at the elbow is normal. The cardinal sign of "tennis elbow" is reproducible pain at the lateral epicondyle on resisted wrist extension. Resisted supination also may be painful.

Management. This condition is often self-limited. Initial therapy consists of avoidance of aggravating activities and a forearm support, which removes stress from the extensor muscle insertion. A wrist extension splint also can help relax the wrist extensors.¹³ As with trochanteric bursitis, NSAIDs have a minimal role. Local anti-inflammatory modalities of physiotherapy, as well as strengthening exercises can be of benefit. Local corticosteroid injections are efficacious and cost-effective (Figure 7). Since this is a superficial injection, multiple injections should be avoided, in order to prevent subcutaneous atrophy and depigmentation. Surgery may be required for resistant cases. **CME**

References

1. Smith DL, Campbell SM: Painful Shoulder Syndromes: Diagnosis and management. *Journal of General Internal Medicine*. 1992; 7 (May/June).
2. Klippel JH: *Rheumatology*. Second edition. Mosby. Copyright 1997, p. 4.7.3.
3. Salzman, KL, Lillegard WF, Butcher JD, et al: Upper Extremity Bursitis. *Am Fam Physician* 1997; 56:1797-1806, 1811-12.
4. Green S: Systematic review of randomised controlled trials of interventions for painful shoulder: selection criteria, outcome assessment, and efficacy. *BMJ* 1998; 316(7128):354-360.
5. Eustace JA et al: Comparison of the Accuracy of Steroid Placement with Clinical Outcome in Patients with Shoulder Symptoms. *Ann Rheum Dis* 1997; 56(1):59-63.
6. Dahan THM, Fortin L, Pelletier C, et al: Double Blind Randomized Clinical Trial Examining the Efficacy of Bupivacaine Suprascapular Nerve Blocks in Frozen Shoulder. *J Rheumatol* 2000; 27:1464-69. Comment on p. 1329-31.
7. Ebenbigher GR, Erdogmus CB, Resch KL, et al: Ultrasound Therapy for Calcific Tendinitis of the Shoulder. *N Engl J Med* 1999; 340:1533-8. Editorial on page 1582.
8. Forbes JR, Helmes CA, Janzen DL, et al: Acute Pes Anserine Bursitis: MR Imaging. *Radiology* 1995; 194:525-527.
9. Toohey, AK, Lasake T, Martine L, et al: Iliopsoas Bursitis: Clinical Features, Radiographic Findings, and Disease Associations. *Seminars in Arthritis and Rheumatism* 1990; 20(1):41-7.
10. Underwood PL, McLeod Ra, Ginsburg WW, et al: The Varied Clinical Manifestations of Iliopsoas Bursitis. *J Rheumatol* 1988; 15:1683-5.
11. Johnston CAM, Wiley JP, Lindsay DM, et al: Iliopsoas Bursitis and Tendinitis. A Review. *Sports Med* 1998; 25(4):271-83.
12. Shbeeb MI, O'Duffy JD, Michet CJ Jr., et al: Evaluation of glucocorticoid injection for the treatment of trochanteric bursitis. *J Rheumatol* 1996; 12:2104-6.
13. Gabel GT: Acute and chronic tendinopathies at the elbow. *Current Opinion in Rheumatology* 1999; 11:138-43.

Suggested readings

1. West SG: *Rheumatology Secrets*. Hanley and Belfus, Inc. Medical Publishers. 1997.
2. Glockner SM: Shoulder Pain: A Diagnostic Dilemma. *American Family Physician* 1995; 51(7):1677-1687.
3. Larsson LG, Baum J: The Syndrome of Anserina Bursitis: An Overlooked Diagnosis. *Arthritis and Rheumatism* 1985; 28(9).
4. Butcher JD, Salzman KL, Lillegard WA, et al: Lower Extremity Bursitis. *American Family Physician* 1996; 53(7):2317-24.
5. Helfgott SM: Unusual features of iliopsoas bursitis. *Arthritis and Rheumatism* 1988; 31(10):1331-1333. Letter.

Put Your Knowledge to the Test

Answer the questions in our quiz found on page 183 and send the response card to the University of Calgary for CME credits.